



PATIENT

Crash Morales

PRESENTING CLINICAL SIGNS

History: Worsening murmur, grade 2-3. Occasional coughing BP: 106, 146, 125mmHg.

SPECIES

Canine

RADIOGRAPHIC FINDINGS *NOTE: Images submitted for supplemental cardiac information only.

A single lateral film is included. Mild cardiomegaly No obvious evidence of CHF.

BREED

Yorkshire Terrier Mix

ELECTROCARDIOGRAPHIC FINDINGS *Note: Single lead ECGs are evaluated as a rhythm strip. Morphology/MEA cannot be definitively commented on.

A single lead ECG is available from an AliveCor monitor; 50mm/s, 20mm/mV. The average heart rate is 100bpm (range 73-123bpm). The rhythm is sinus in origin, with a p for every QRS complex and vice versa. The P and QRS morphologies are positive with normal dimension. No ectopic beats, pauses or dysrhythmias observed.

ECG diagnosis: Normal sinus rhythm with respiratory variation.

SEX

Male Neutered

ECHOCARDIOGRAM FINDINGS

2D, m-mode, color flow and doppler imaging is available. Mild diffuse thickening of mitral valve leaflets with no prolapse into the left atrial lumen. Mild anterior-directed mitral regurgitation with mild left atrial dilation. Normal MR velocity. Normal LV diameter with adequate myocardial function. The tricuspid valve appears normal with mild tricuspid regurgitation. Normal right atrial and ventricular diameter and morphology indicating no overt evidence of pulmonary arterial hypertension. The pulmonic and aortic valves are normal in morphology and mobility. Normal pulmonic and aortic outflow velocities with laminar flow. No obvious aortic or pulmonic insufficiency. No pericardial or pleural effusion noted. No obvious cardiac masses.

AGE

15 years

WEIGHT

10lbs

CARDIAC CHART

INTERPRETED BY

Maggie Machen
Lamy, DVM, DACVIM
(Cardiology)

CANINE CARDIAC PARAMETERS	MR VMAX (m/s)	TR VMAX (m/s)	LA/AO (Boon method)	LA/AO (Heart Base; Swe)	FS (%)	EF (%)	EPSS (cm)
NORMAL PARAMETER	4.5-5.5	<2.7	1.3	<1.6	28-40	40-100	<0.6
PATIENT	5.1	NM	NM	1.45	34	66	0.16
CANINE CARDIAC PARAMETERS	HR (BP M)	AV VMAX (m/s)	PV MAX (m/s)	BODY WEIGHT (kg)	LA 2D short axis Base view (cm)	LVIDd Avg; 2D and m-mode short axis (cm)	LVIDs Avg; 2D and m-mode short axis (cm)
NORMAL PARAMETER	50-100	0.7-1.7	0.7-1.6	BELOW	BELOW	BELOW	BELOW
PATIENT	NM	1.7	0.9	4.5	1.7	2.6	1.7
*Normal chamber parameters expressed as a mean value				3	1.27	2.46	1.36
BODY WEIGHT DEPENDENT PARAMETERS							
*Note: All measurements based upon multi-modal images and methods. An average value is reported.							
Adapted from June Boon, Veterinary Echocardiography, 1998 Rishniw M and Hollis NE, J Vet Intern Med 2000; 14:429-435 Hansson et al, Vet Rad and Ultrasound 2002 Bonagura et al. Echocardiography: principles of interpretation, Vet Clin North Am 15:1177, 1995				5	1.40	2.74	1.60
				10	1.50	3.27	2.06
				15	1.83	3.71	2.43
				20	2.02	4.14	2.80
				25	2.18	4.48	3.10
				30	2.33	4.83	3.39
				35	2.48	5.17	3.69
				40	2.62	5.48	3.96
				50	2.88	6.07	4.46

IMAGING PERFORMED BY

Rebekah Jakum, CVT
ARDMS/RVT

HOSPITAL NAME

Pocono Peak VC

REFERRING VET

Dr. Coyle

INVOICE

30677

DATE

5/9/23

INTERPRETATION OF THE FINDINGS & FURTHER RECOMMENDATIONS



PATIENT

Crash Morales

Chronic degenerative valve disease causing mild mitral and tricuspid regurgitation. Lack of left atrial enlargement indicates the current risk for complication is low. No concurrent issues such as systolic dysfunction or pulmonary hypertension are noted in this study. The ECG is unremarkable with a respiratory sinus arrhythmia.

SPECIES

Canine

Given these findings, the cough is unlikely to be cardiac in origin and primary respiratory causes should be considered. Consider further respiratory work up/treatment (hydrocodone, taper course of steroids, Enrofloxacin, TTW/BAL, etc.).

BREED

Yorkshire Terrier Mix

In a dog with no significant left atrial enlargement, no cardiac medications are clearly indicated. Omega fatty acid supplementation and mild salt restriction may be of some long term benefit. Monitor for development of a cough, labored breathing, exercise intolerance or collapse episodes.

SEX

Male Neutered

Anesthetic risk is considered mild. Cardiac protective drug choices (opioid/benzodiazepine premedication, propofol or alfaxalone induction, isoflurane gas) are recommended. Pre-oxygenate for 5-10 minutes prior to induction. Monitor for arrhythmias, hypotension, and hypoxia both intra and post-operatively and intervene as necessary. Mild IV fluid restriction is recommended to avoid fluid overload. Avoid heart rate stimulating drugs such as atropine unless clinically indicated.

AGE

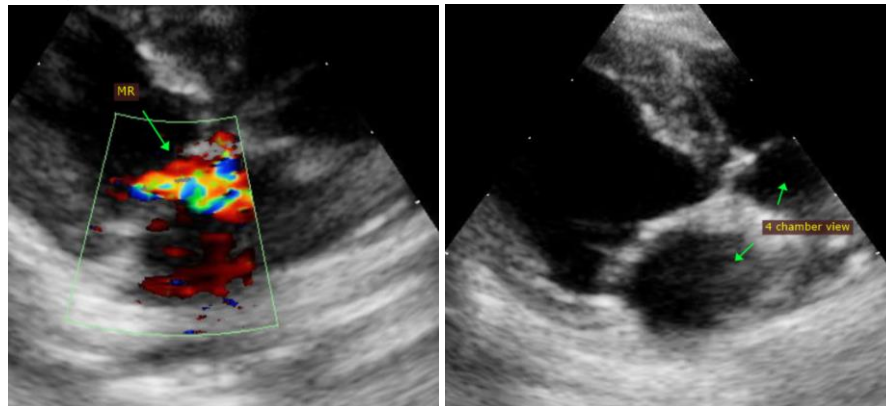
15 years

Recommend conservative monitoring with a recheck echocardiogram in 6 months, sooner if any development of clinical signs.

WEIGHT

10lbs

IMAGES



INTERPRETED BY

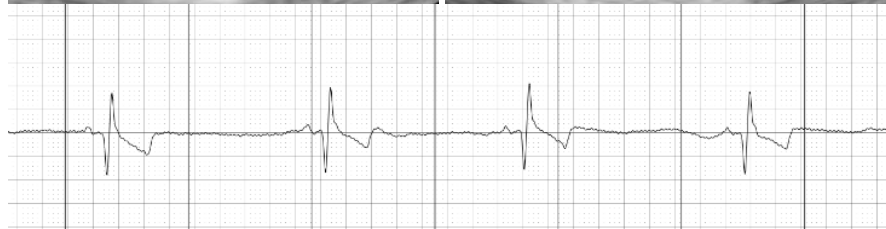Maggie Machen
Lamy, DVM, DACVIM
(Cardiology)

IMAGING PERFORMED BY

Rebekah Jakum, CVT
ARDMS/RVT

HOSPITAL NAME

Pocono Peak VC



REFERRING VET

Dr. Coyle

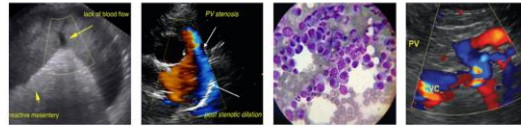
INVOICE

30677

DATE

5/9/23

The information and recommendations provided are based on the images presented by the referring veterinarian. No evaluation can be communicated regarding pathology that was not visible in the image/video clips provided.



PATIENT

Crash Morales Thank you for this referral. If the clinical or image interpretation does not parallel your findings or if I can be of any further assistance, please contact me.

SPECIES

Canine **Maggie Machen Lamy, DVM**
Diplomate of the American College of Veterinary Internal Medicine (Cardiology)
info@sonopath.com

BREED

Yorkshire Terrier Mix

SEX

Male Neutered

AGE

15 years

WEIGHT

10lbs

INTERPRETED BY

Maggie Machen
Lamy, DVM, DACVIM
(Cardiology)

**IMAGING
PERFORMED BY**

Rebekah Jakum, CVT
ARDMS/RVT

HOSPITAL NAME

Pocono Peak VC

REFERRING VET

Dr. Coyle

INVOICE

30677

DATE

5/9/23